

Hyperactive Dental Lamina in a 24-Year-old Female – A Case Report and Review of Literature

ASHU GUPTA¹, PRIYA NAGAR², RAKSHIT VIJAY SINAI KHANDEPARKER³, DEEPTI MUNJAL⁴, HARSIMRAN SINGH SETHI⁵

ABSTRACT

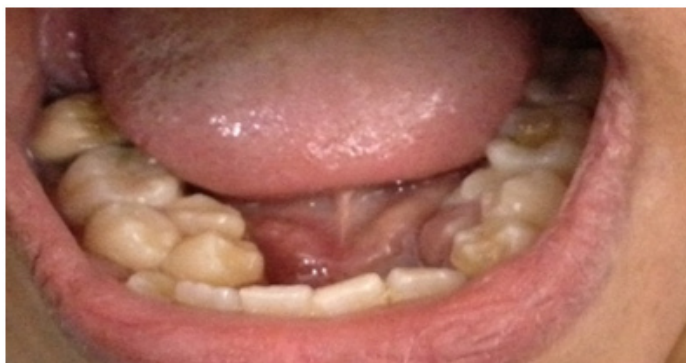An extra tooth to the normal formula of teeth sequence in any region of dental arch is regarded as Supernumerary teeth (ST). The reasons are still not clearly known, one of them being dichotomy of tooth bud, but the more accepted reason is the hyperactivity theory. Supernumerary teeth are present more in permanent dentition than in primary dentition and can present as a single entity or multiple, unilaterally or bilaterally, impacted or erupted, in either or both the dental arches. This article discusses the supernumerary teeth in detail with a case discussion of a non-syndromic 24-year-old girl, with six ST (bicuspid) present in all the four quadrants. In the mandible, ST's showed a classical clustered flower like presentation. The interesting feature in the presented case was the sequential orthopantomographs taken at various ages of the patient that showed continuous development of STs in all four quadrants, thus pointing to the theory of hyperactive dental lamina or atavism. An electronic search was conducted in PubMed, Cochrane Library and google scholar databases, and articles dated between December 1932 and December 2012 were selected to review the occurrence patterns of supernumerary teeth in non-syndromic cases.

Keywords: Atavism, Hyperdontia, Supernumerary teeth, Tooth bud splitting

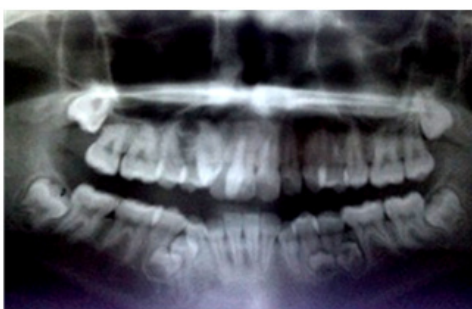CASE REPORT

A 24-year-old girl reported to the clinic with pain in her lower right molar. A periapical abscess was diagnosed and root canal was performed followed with crown placement for the respective tooth. But during the initial examination, multiple supernumerary premolars were noted on either sides of the mandible, which had a classical clustered flower like presentation [Table/Fig-1]. No medical history was found significant and thus any syndrome or systemic condition was ruled out completely. The patient did not

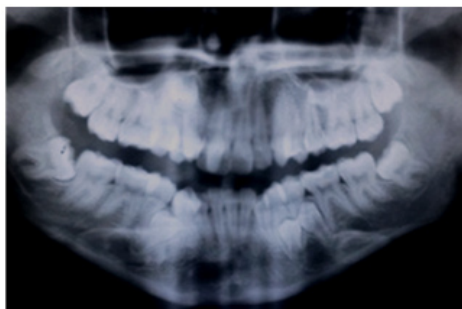
report any similar familial history. Patient told that due to various dental problems over the years regular orthopantomographs were taken at different ages [OPG at the age of 14 [Table/Fig-2] and 17 years [Table/Fig-3]]. A new OPG was also taken when the patient first reported to the clinic. On careful examination of all the OPGs {only the latest one being digital at 24 years of age, [Table/Fig-4]}, it was concluded that there was dental lamina formation around the premolar region of maxilla and mandible, which later developed into premolars. These supplemental teeth could not be identified as odontomas as they have shape, structure and tissue differentiation similar to premolars and much resemblance that it was difficult to differentiate between actual premolars and the supplemental ones, on clinical and radiographic examination. Occlusal radiographs revealed that these teeth were not fused, but were separate supplementary teeth. In case of maxilla the supplemental premolars were found to be impacted and were present close to the sinus lining. No association with cyst or any other lesion was found thus maxillary supplemental premolars were decided to be left in situ for the time being, with regular radiographic and clinical follow-up. For mandibular supernumerary teeth removal was planned with patient's approval. No new tooth buds were noted anywhere in maxilla or mandible. Regular follow up every year was advocated to see any further changes in the dentition.



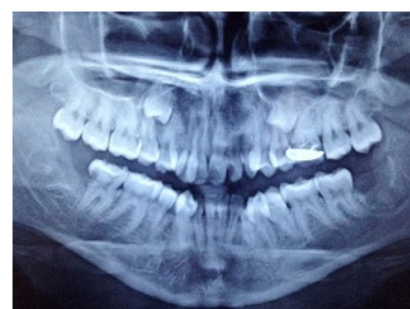[Table/Fig-1]: Intra oral picture showing the lower supplemental teeth and cluster formation at the age of 24 years



[Table/Fig-2]: Orthopantomograph of the patient taken at 14 years showing supernumerary teeth in mandible and maxilla



[Table/Fig-3]: OPG of the patient taken at 17 years showing new tooth buds in maxilla which was not present at the age of 14 years



[Table/Fig-4]: OPG of the patient taken at 24 years showing tooth buds in maxilla and supernumerary teeth both in maxilla and mandible

DISCUSSION

Hyperdontia is used to describe supernumerary or extra teeth that develop in supplement to the 20 deciduous and 32 Permanent teeth [1]. Atavism is one of the theories for the formation of supernumerary teeth. Atavism is the tendency to revert to ancestral characters. It is considered as reappearance of lost characters or traits which had disappeared generations before or which are not observed in the parents or recent ancestors of the organism displaying the atavistic character [2]. The other theories include tooth bud splitting and an amalgamation of circumstantial and genetics factors [3-6]. However according to Gardiner the late developing post permanent teeth, develop from the conception of the dental lamina after the permanent dentition is concluded in its formation [7].

In the present case the tooth buds kept appearing and finally teeth developed and erupted at various stages of the patient's life. This unique feature prompted the authors to report the case, as the treatment of supernumerary teeth in this present case was not only extraction of the respective tooth, but it also requires a long term follow up, along with orthopantomographs (OPGs) at various time intervals to rule out the possibility of the hyperactive dental lamina which might cause more supernumerary teeth to appear in the jaw even at the later stages of the patient's life.

An extensive research was made into the review of literature on case reports of multiple supernumerary teeth and total 65 articles were selected including 40 case reports. Exclusion criteria were: cases which presented clinical or radio-graphical signs of any syndrome. Inclusion criteria were: cases which reported three or more erupted or non-erupted supernumerary teeth. PubMed, Cochrane Library and google scholar databases, and papers dated between December 1932 and December 2012 were selected to review the occurrence patterns of supernumerary teeth in non-syndromic cases. Data was recorded under different columns, author, year, age, gender, total number of teeth, teeth present in maxilla and mandible [Table/Fig-5] [8-49].

Prevalence of the supernumerary in permanent dentition has been found to be 0.26% and it has been seen that 70% of all supernumerary cases are premolars [50]. The occurrence of supernumerary teeth is more in case of mandible as compare to maxilla [51]. It has been found that prevalence of single supernumerary teeth accounts for 86% cases, for double is 12% cases and for multiple supernumerary teeth it has been found to be less than 1% cases. Also, the prevalence of supernumerary teeth was found to be more frequent in males than females, the ratio being 1:2.3 [15,50,52].

Supernumerary teeth may occur with or without syndromes Gardner's syndrome, Cleidocranial syndrome and developmental conditions such as lip and palate fissure. However, non-syndromic multiple supernumeraries are rarely encountered [53-56]. In the present case patient had insignificant medical history thus possibilities of any syndromes was ruled out. The theories of formation of supernumerary teeth include atavism, splitting of the tooth bud and a combination of genetic and environmental factors. The most accepted theory is hyperactivity of the dental lamina. According to Gardiner, late developing (post permanent) supernumerary teeth develop from the proliferation of the dental lamina after the permanent dentition is completed [15,57,58]. In the present case, the 24-year-old female patient when reported to the clinic had two supernumerary teeth in the lower jaw. The previous sequential OPGs revealed that these supernumerary teeth were not present earlier, but had developed recently which showed that the patient had hyperactive dental lamina. This may be the cause of continually developing teeth in her jaw and the condition might continue to develop more teeth. Moreover, as the patient had no clinical symptoms like pain or swelling etc., but the clustered flower like appearance of mandibular premolars on either sides of the dental arch seemed to show that there were two or more supernumerary teeth on either side of the jaw. The patient also noticed that these teeth appeared just few years back and each one in a span of time after the first one. Also, the sequential OPGs taken at various ages show no tooth buds at earlier ages and there

Author	Year	Gender, Age	No. of Teeth	Maxilla	Mandible	Anterior	Premolar / Bicuspids	Molar	Distomolars	Mesiodens
Maity S et al., [8]	2015	M,27	8	6	2	0	5	1	1	0
Vinodhkumar P et al., [9]	2014	M,50	4	1	3	1	3	0	0	0
Vinodhkumar P et al., [9]	2014	M,35	3	0	3	0	3	0	0	0
Santosh et al., [10]	2012	M,35	3	0	3	0	3	0	0	0
Ledesma-Montes et al., [11]	2012	F,12	12	1	11	4	6	2	0	0
Ferriol et al., [12]	2011	F,12	14	5	9	2	8	4	0	0
Ferriol et al., [12]	2011	M,20	12	6	6	0	12	0	0	0
Kaya et al., [13]	2011	F,39	5	1	4	0	5	0	0	0
Inchingolo et al., [14]	2010	F,17	5	3	2	0	0	5	0	0
Hyun et al., [15]	2008	M,13	6	2	4	0	6	0	0	0
Hyun et al., [15]	2008	F,20	5	0	5	0	5	0	0	0
Hyun et al., [15]	2008	M,17	5	0	5	0	5	0	0	0
Sivapatha sundharam & Einstein [16]	2007	M,20	14	5	9	2	12	0	0	0
Srivatsan and Aravindh Babu [17]	2007	F,19	10	2	8	2	6	2	0	0
Wang et al., [18]	2007	F,11	16	8	8	0	14	0	2	0
Acikgoz et al., [19]	2006	M,27	8	4	4	1	7	0	0	0
Acikgoz et al., [19]	2006	M,20	7	4	3	0	7	0	0	0
Acikgoz et al., [19]	2006	M,17	5	2	3	2	3	0	0	0
Acikgoz et al., [19]	2006	M,33	6	2	4	1	5	0	0	0
Acikgoz et al., [19]	2006	M,20	6	1	5	0	6	0	0	0
Acikgoz et al., [19]	2006	M,22	5	3	2	2	3	0	0	0

Nayak & Mathian [20]	2006	M,13	13	6	7	1	10	2	0	0
Batra et al., [21]	2005	F,17	11	3	8	2	8	0	0	1
Batra et al., [21]	2005	M,20	8	0	8	4	4	0	0	0
Arathi & Ashwini [22]	2005	M,12	12	5	7	3	9	0	0	0
Bartleman [23]	2005	M,18	12	6	6	2	10	0	0	0
Manrique Mora [24]	2004	M,12	5	1	4	0	5	0	0	0
So [25]	2003	M,15	11	2	9	2	9	0	0	0
Ng'ang'a et al., [26]	2002	M,14	8	4	4	0	8	0	0	0
Ng'ang'a et al., [26]	2002	F,13	7	2	5	0	5	2	0	0
Arcuri et al., [27]	2002	F,09	13	8	5	1	7	2	2	1
Duffy [28]	2001	M,23	13	6	7	1	12	0	0	0
Sharma [29]	2001	F,12	11	7	4	5	6	0	0	0
Desai & Shah [30]	1998	M,36	16	9	7	2	6	5	2	1
Desai & Shah [30]	1998	M,25	7	5	2	0	4	3	0	0
Mercury & O'Neil [31]	1998	F,17	11	3	8	0	8	0	2	1
Rizzuti & Scotti [32]	1997	M,10	22	11	11	9	10	0	3	0
Mason et al., [33]	1996	M,15	16	6	10	2	11	0	3	0
Mason et al., [33]	1996	F,12	5	3	2	0	4	1	0	0
Mason et al., [33]	1996	M,15	5	2	3	0	5	0	0	0
Hopcraft [34]	1996	M,18	10	3	7	0	8	2	0	0
King et al., [35]	1993	F,13	6	3	3	0	6	0	0	0
King et al., [35]	1993	M,18	6	4	2	0	6	0	0	0
King et al., [35]	1993	M,30	8	3	5	0	8	0	0	0
Reichart [36]	1992	M,18	7	4	3	0	7	0	0	0
Yucel [37]	1992	M,22	6	1	5	0	6	0	0	0
Yusof & Awang [38]	1990	M,24	16	5	11	0	11	5	0	0
Yusof & Awang [38]	1990	F,22	10	3	7	0	8	2	0	0
Fitzgerrald & Zallen [39]	1990	M,20	12	5	7	3	8	0	1	0
Acton [40]	1987	M,24	7	4	3	0	1	6	0	0
Leslie [41]	1984	M,25	6	2	4	0	3	3	0	0
Rosenthaler & Berdeman [42]	1983	F,26	6	6	0	0	4	2	0	0
Stevenson & Mckechnie [43]	1980	M,10	12	6	6	1	7	0	0	4
Shusterman et al., [44]	1978	F,07	6	4	2	4	2	0	0	0
Folley & del Rio [45]	1978	M,22	16	10	6	4	8	2	2	0
Stevenson & Mckechnie [46]	1975	M,10	11	6	5	5	6	0	0	0
Barnet [47]	1974	M,12	6	2	4	0	2	4	0	0
Finkel et al., [48]	1974	M,24	9	3	6	0	6	3	0	0
Ruhlman & Neely [49]	1964	M,14	9	6	3	6	3	0	0	0

[Table/Fig-5]: Data Set for Supernumerary Teeth

was sequential appearance of buds in later life of the patient which highlight the fact that dental lamina proliferation occurred after the completion permanent dentition.

The associated syndromes and developmental conditions with supernumerary teeth include cleidocranial dysplasia, Gardner's syndrome, cleft lip and cleft palate [15,57,58]. Supernumerary teeth are usually asymptomatic and in most cases are diagnosed by chance. Bodin reported only 2% of supernumerary teeth undergo pathological changes [54]. Nevertheless, the most commonly encountered complications with these teeth are dentigerous cyst and root resorption of the adjacent tooth [59]. However, in the present case such findings were not present.

Pain might occur due to pressure caused by supernumerary teeth on the adjoining teeth and their proximity to the mental and inferior dental nerves. Some authors suggest that removal of these teeth is the only method of treatment. The timing of removal is important. Whenever these teeth are associated with any pathological changes

or whenever they hinder eruption of, or cause mal-position of permanent teeth and removal outweighs benefits they should be removed [12,19,21,38,60,61].

Rajab LD et al., carried study and found that males are affected more than female with a sex ratio of 2:1.1 [15]. In the present literature review, frequency of supernumerary teeth in mandible was found to be more as compared to maxilla. The ratio varies widely from 11.1% to 1% [62,63]. Yusuf found that supernumerary teeth were more frequent in mandible [38], Ackigoz reported 56.8% in mandible [19], whereas Nazif reported 14% but all in maxillary region [60]. Acikgoz noted another interesting feature of the condition, as bilateralism of non syndromic supernumerary teeth which is also seen in present case [19].

CONCLUSION

Supernumerary teeth can be discovered at any age and can lead to occlusal and other clinical defects such as hindrance in eruption

and displacement of nearby permanent teeth of that region of the dental arch. Regular follow-ups, with OPGs should be done even in the cases where supernumerary teeth have been removed, to eliminate the case of hyperactive dental lamina, which may cause more teeth to develop in the jaw.

REFERENCES

- [1] Schulze C. Developmental abnormalities of the teeth and jaws. In: Thoma's Oral Pathology. 6th ed. Gorlin RJ, Goldman HM, editors. St Louis, Mo: CV Mosby 1970. Pp. 112-22.
- [2] Hall BK. Developmental mechanisms underlying the formation of atavisms. *Biol Rev*. 1984;59:89-124.
- [3] Moore SR, Wilson DF, Kibble J. Sequential development of multiple supernumerary teeth in the mandibular premolar region -- a radiographic case report. *Int J Paediatr Dent*. 2002;12:143-45.
- [4] Gunduz K, Muglali M. Non-syndrome multiple supernumerary teeth: A report. *J Contemp Dent Pract*. 2007;8:81-87.
- [5] Yague-Garcia J, Berini-Ayres L, Gay-Escoda C. Multiple supernumerary teeth not associated with complex syndromes: a retrospective study. *Med Oral Patol Oral Cir Bucal*. 2009;14:331-36.
- [6] Diaz A, Orozco J, Fonseca M. Multiple hyperodontia: report of a case with 17 supernumerary teeth with non syndromic association. *Med Oral Patol Oral Cir Bucal*. 2009;14:229-31.
- [7] Gardiner JH. Supernumerary teeth. *Dent Pract*. 1961;12:63-73.
- [8] Maity S, Kashyap RR, Naik V, Kini R, Begum N. Multiple Permanent Impacted Supernumerary Teeth in a Non-Syndromic Patient- A Case Report with a Review of Literature. *International Journal of Advanced Dental Science and Technology*. 2015;2(1):47-52.
- [9] Vinodkumar P, Shruthi BS. Occult Multiple Supernumerary Premolar Teeth: Two Case Reports of Post Permanent Dentition. *World Journal of Medical Sciences*. 2014;10(2):233-37.
- [10] Mali S, Karjodkar FR, Sontakke S, Kaustabh S. Supernumerary teeth in non-syndromic patients. *Imaging Sci Dent*. 2012;42(1):41-5.
- [11] Ledesma-Montes C, Salcido-Garcia FP, Hernandez-Flores F, Garces-Ortiz M. Multiple Supernumeraries in a Non-syndromic Patient. *J Clin Pediatr Dent*. 2012;37(2):193-95, No. 2/2012.
- [12] Ferriol-Fiol MN, Xavier S, Figueiredo R, Valmaseda-Castellon E, Gay-Escoda C. Non-syndromic multiple supernumerary teeth: meta-analysis. *Med Oral Patol Oral Cir Bucal*. 2011;16:89-93.
- [13] Kaya GS, Yapici G, Omezil MM, Dayi E. Non-syndromic supernumerary premolars. *Med Oral Patol Oral Cir Bucal*. 2011;16:e522-25.
- [14] Inchigolo F, Tatullo M, Abenavoli FM, et al., Non Syndromic multiple supernumerary teeth in a family unit with a normal karyotype: case report. *Int J Med Sci*. 2010;7:378-84.
- [15] Rajab LD, Hamdan MA. Supernumerary teeth: Review of the literature and a survey of 152 cases. *Int J Paediatr Dent*. 2002;12:244-54.
- [16] Sivapathasundharam B, Sinstein A. Non-syndromic multiple supernumerary teeth: report of a case with 14 supplemental teeth. *Indian J Dent Res*. 2007;18:144.
- [17] Srivatsan P, Aravindh Babu N. Mesiodens with an unusual morphology and multiple impacted supernumerary teeth in a non-syndromic patient. *Indian J Dent Res*. 2007;18:138-40.
- [18] Wang XX, Zhang J, Wei FC. Autosomal dominant inheritance of multiple supernumerary teeth. *Int J Oral Maxillofac Surg*. 2007;36:756-58.
- [19] Acikgoz A, Acikgoz G, Tunga U, Otan F. Characteristics and prevalence of non-syndromic multiple supernumerary teeth: a retrospective study. *Dento-maxillofac Radiol*. 2006;35:185-90.
- [20] Nayak UA, Mathain VM, Ceerakumar C. Non-syndrome associated multiple supernumerary teeth: A report for two cases. *J Indian Soc Pedo Prev Dent*. 2006;24(2):11-14.
- [21] Batra P, Duggal R, Parkash H. Non-syndromic multiple supernumerary teeth transmitted as an autosomal dominant trait. *J Oral Pathol Med*. 2005;34:621-5.
- [22] Arathi R, Ashwini R. Supernumerary teeth. A case report. *J Indian Soc Pedod Prevent Dent*. 2005;23:103-05.
- [23] Bartleman FC. Supernumerary teeth. *Dental Cosmos*. 1932;74:1028.
- [24] Manrique MC, Bolanos Carmona MV, Briones Lujan MT. Molarization and development of multiple supernumerary teeth in the premolar region. *J Dent Child (Chic)*. 2004;71:171-74.
- [25] So LL. Unusual supernumerary teeth. *Angle Orthod*. 1990;60:289-92.
- [26] Nganga PM, Guthua SW, Nganga RN. Multiple supernumerary teeth in association with malocclusion: report of two cases. *East Afr Med J*. 2002;79:221-23.
- [27] Arcuri C, Muzzi F, Romanini G, Cecchetti F, Pujja A, Giancotti A. Supernumerary teeth diagnosis and treatment approach. Six case reports. *Minerva Stomatol*. 2002;51:501-72.
- [28] Duffy MT. Multiple impacted supernumerary teeth. *Oral Surg Oral Med Oral Pathol*. 1973;35:433-34.
- [29] Sharma A. A rare non syndrome case of concomitant multiple supernumerary teeth and partial anodontia. *J Clin Pediatr Dent*. 2001;25:167-69.
- [30] Desai RS, Shah NP. Multiple supernumerary teeth in two brothers: a case report. *J Oral Pathol Med*. 1998;27:411-13.
- [31] Mercuri LG, O'Neill R. Multiple impacted supernumerary teeth. *Oral Surg Oral Med Oral Pathol*. 1980;50:293.
- [32] Rizutti N, Scotti S. A case of hyperodontia with twenty two supernumeraries: its surgical-orthodontic treatment. *Am J Orthod Dentofacial Orthop*. 1997;111:471-80.
- [33] Mason C, Rule DC, Hopper C. Multiple supernumeraries: the importance of clinical and radiographic follow-up. *Dentomaxillofac Radio*. 1996;25:109-13.
- [34] Hopcraft M. Multiple Supernumerary teeth. Case Report. *Aust Dent J*. 1998;43:17-19.
- [35] King NM, Lee AM, Wan PK. Multiple supernumerary premolars: their occurrences in 3 patients. *Aust Dent J*. 1993;38:11-16.
- [36] Reichart PA. Duplication of all permanent premolars. *Oral Surg Oral Med Oral Pathol*. 1982;53:437.
- [37] Yucel E. Multiple supplemental premolars. *Oral Surg Oral Med Oral Pathol*. 1992;74:384.
- [38] Yusuf WZ, Awang MN. Multiple impacted supernumerary teeth. *Oral Surg Oral Med Oral Pathol*. 1990;70:126.
- [39] Fitzgerald BE, Zallen RD. Multiple impacted supernumerary teeth. *Oral Surg Oral Med Oral Pathol*. 1978;46:733.
- [40] Acton CH. Multiple Supernumerary teeth and possible implications. *Aust Dent J*. 1987;32:48-49.
- [41] Leslie JC. Multiple supernumerary teeth. *Oral Surg Oral Med Oral Pathol*. 1984;57:463.
- [42] Rosenthaler H, Beideman RW. Multiple supernumerary teeth. *Oral Surg Oral Med Oral Pathol*. 1983;56:227.
- [43] Stevenson W, Mckechnie AD. Recurring supernumerary and impacted teeth. *Quintessence Intl*. 1980;11:85-87.
- [44] Shusterman S, Hertzberg J, Hilzenrath S. Multiple supernumerary teeth: report of 2 cases. *ASDC J Dent Child*. 1978;45:469-72.
- [45] Folley MF, del Rio CE. Supernumerary teeth: report of a case. *Oral Surg*. 1970;30:60-63.
- [46] Stevenson W, Mckechnie AD. Recurring supernumerary teeth: report of a case. *Oral Surg Oral Med Oral Pathol*. 1975;40:76-80.
- [47] Barnett BS. A case of multiple supernumerary premolars. *Br J Orthod*. 1974;1:217-18.
- [48] Finkel AN, Soloncz G, Friedman J. Multiple supernumerary and impacted teeth. *Oral Surg Oral Med Oral Pathol*. 1974;37:976-77.
- [49] Ruhman DG, Neely AR. Multiple impacted and erupted supernumerary teeth. Report of a case. *Oral Surg Oral Med Oral Pathol*. 1964;17:199-203.
- [50] Hyun HK, Lee SJ, Ahn BD, Lee ZH, Heo MS, Seo BM, et al. Nonsyndromic multiple mandibular supernumerary premolars. *J Oral Maxillofac Surg*. 2008;66:1366-69.
- [51] Yousof WZ. Non-syndromal multiple supernumerary teeth: Literature review. *J Can Dent Assoc*. 1990;56:147-49.
- [52] Sasaki H, Funao J, Morinaga H, Nakano K, Ooshima T. Multiple supernumerary teeth in the maxillary canine and mandibular premolar regions: a case in the postpermanent dentition. *Int J Paediatr Dent*. 2007;17:304-08.
- [53] Ferrer-Padro E, Prats-Armengol J, Ferrer-Amat E. A descriptive study of 113 unerupted supernumerary teeth in 79 pediatric patients in Barcelona. *Med Oral Patol Oral Cir Bucal*. 2009;14:146-52.
- [54] Bodin I, Julin P, Thomsson M. Hyperodontia. I. Frequency and distribution of supernumerary teeth among 21,609 patients. *Dentomaxillofac Radiol*. 1978;7(1):15-17.
- [55] Salcido-Garcia JF, Ledesma-Montes C, Hernandez-Flores F, Perez D, Garces-Ortiz M. Frequency of supernumerary teeth in Mexican population. *Med Oral Patol Oral Cir Bucal*. 2004;9:407-09.
- [56] Aneundi RT, Tavargeri A, Indushekar KR, Sudha P. Sequential development of multiple supplemental premolars. Four-year follow-up report. *N Y State Dent J*. 2008;74:46-49.
- [57] Zhu JF, Marcushamer M, King LD, Henry JR. Supernumerary and congenitally absent teeth: A literature review. *J Clin Pediatr Dent*. 1996;20:87-95.
- [58] Hegde SV, Munshi AK. Late development of supernumerary teeth in premolar region: A case report. *Quintessence Intl*. 1996;27:479-81.
- [59] Solares R, Romero MI. Supernumerary premolars: a literature review. *Pediatr Dent*. 2004;26:450-58.
- [60] Nazif MM, Ruffalo RC, Zullo T. Impacted supernumerary teeth: a survey of 50 cases. *J Am Dent Assoc*. 1983;106:201-04.
- [61] Joaquin Alvira G, Cosme Gay E. Non-syndromic multiple supernumerary teeth: meta-analysis. *J Oral Pathol Med*. 2012;41:361-66.
- [62] Scheiner MA, Sampson WJ. Supernumerary teeth: a review of the literature and four case reports. *Aust Dent J*. 1997;42:160-65.
- [63] Asaumi J, Shabita Y, Yanagi Y, Hisatomi M, Matzizami H, Konouchi H, et al. Radiographic examination of mesiodens and their associated complication. *Dentomaxillofac Radiol*. 2004;33:125-27.

PARTICULARS OF CONTRIBUTORS:

1. Reader, Department of Pedodontics, DJ Dental College, Modinagar, Ghaziabad India.
2. Reader, Department of Pedodontics, Krishnadevaraya College of Dental Sciences, Bangalore, India.
3. Consultant, Department of Oral and Maxillofacial Surgeon, Goa, India.
4. Senior Lecturer, Department of Pedodontics, Maharaja Ganga Singh Dental College and Research Centre Sri Ganganagar, Rajasthan, India.
5. Senior Lecturer, Department of Pedodontics, Maharaja Ganga Singh Dental College and Research Centre Sri Ganganagar, Rajasthan, India.

NAME, ADDRESS, E-MAIL ID OF THE CORRESPONDING AUTHOR:

Dr. Harsimran Singh Sethi,
Senior Lecturer, Department of Pedodontics, Maharaja Ganga Singh Dental College and Research Centre,
Sriganganagar-335001, Rajasthan, India.
E-mail : sethiharsimranpedo@yahoo.in

FINANCIAL OR OTHER COMPETING INTERESTS: None.

Date of Submission: **Apr 26, 2015**
Date of Peer Review: **Jun 01, 2015**
Date of Acceptance: **Jul 07, 2015**
Date of Publishing: **Aug 01, 2015**